

# Exoskeleton Derivatives of Mammals

## TIG

The following points highlight the the seven main integumentary derivatives in mammals. The integumentary derivatives are: 1. Glands 2. Hair 3. Colour 4. Claws, Nails and Hoofs 5. Horns 6. Antlers 7. Epidermal Scales.

### Integumentary Derivative:

#### 1. Glands:

A large variety of epidermal glands is present in the skin of mammals. These glands are tubular or alveolar in nature and are always multicellular.

The principal glands are:

#### a. Sudorific or sweat glands:

These are long and coiled tubular glands. The lower part of the gland lies embedded in the dermis and the upper part is constituted by a duct which opens to the outside through a pore. The distribution of sweat glands in different mammals is not uniform. In case of man the sweat glands are more numerous on palm, sole and arm pits.

In cat, dog and rat sweat glands are more numerous on palm, sole and arm pits. In cat, dog and rat sweat glands are found in the sole of the feet. In rabbits the glands are found around the lips.

The ruminants have sweat glands located on the muzzle and on the interdigital fold of skin. In hippopotamus the pinna houses the sweat glands.

Sweat glands are absent in Tachyglossus, Mus, Talpa, Cetacea and Sirenia. The sweat is watery in appearance but its colour is red in certain mammals like hippopotamus and Macropus.

Function:

The secretion of sweat glands is known as sweat. Sweat aids in removing nitrogenous wastes and helps in the regulation of body temperature. It is believed that the **glands of Moll in the eye margin of man are modified sweat glands and similar is the case with ceruminous or wax- secreting glands in the external ear passage.**

#### **b. Sebaceous glands:**

The glands are alveolar in nature and are generally associated with the hair. But they occur in hairless parts of the body, i.e., around the genital organ, tip of the nose and border of lips, independently. **These glands are absent in Pangolin, Cetacea and Sirenia.**

Function:

The secretion of the gland is known as sebum. It is oily in nature and helps in keeping the body oily. **Meibomian glands in the eyelids are modified sebaceous glands.** It secretes an oily film on the surface of the eyeball. Scent glands too are modified sebaceous glands.

**The secretion of scent glands is sex attractants. They are situated on the different parts of the body. In the deer family scent glands are located near the eyes. In carnivores scent glands are found near the anus. The pigs and goats have scent glands in between their toes.**

#### **c. Mammary glands:**

The mammary or milk- producing glands are found in all mammals. The mammary glands are built on the same general plan though variations occur. Each gland is made up of a number of lobules. Each lobule consists of a number of alveoli which contain the secretory cells. The

small ducts emerging from the alveoli gradually converge to form a large duct.

Many such large ducts unite and form a common duct which opens to the outside through the nipple. The ducts and alveoli remain surrounded by abundant adipose tissue and contribute to the size of the mammae or breast of the females.

The secretion of the mammary gland is milk. Mammary glands are active only at certain times—immediately after the young are born and generally as long as active suckling by the young continues. The development and functioning of the mammary glands are controlled by hormones secreted by the ovaries, anterior lobe of pituitary and adrenal cortex.

Mammary glands are compound tubular type in Prototheria and they lack nipples and as a result, the glands open directly on the body surface. In Prototheria, mammary area is depressed, in Metatheria and Eutheria nipples are always present.

Mammary glands are distributed along a milk line which appears on either side of the body extending from the base of the pectoral limb bud and pelvic limb bud during early embryonic development.

There may be a single pair of mammary glands as in man and there may be as many as eleven pairs of mammary glands as in certain insectivores. The distribution of mammary glands is related to the habit of the mother when nursing her young and, thus, may be axillary, thoracic, abdominal or inguinal in position.

## 2. Hair:

Hair is a mammalian monopoly. During embryonic development in all mammals the body becomes covered with a coating of fine hair called

Lanugo. The **lanugo hairs** are absent on the ventral surfaces of hand and feet. The lanugo hairs are transient and are shed sometimes before birth. The second set of hair then appears.

Collectively all the hairs covering the body of a mammal, is called as pelage. In most mammals the entire integument remains covered with hairs, but in some the hairy coat is secondarily lost and only traces remain.

Thus, in some adult and large whales a few coarse hair is present near the snout. Such a condition is known as **Hypotrichosis**. Failure of hairs to develop leads to **Atrichosis** condition. Occasionally, such human beings are found. Presence of excess of hair is called **Hypertrichosis**.

Development:

Hair is entirely epidermal in origin:

During development a small thickening in the epidermis pushes down into the dermis. The depression becomes cup-shaped and the dermis rushes into this cup-shaped depression to make up the hair papilla. The blood vessels which enter the papilla bring nourishment to the cells of the stratum germinativum.

As this process is going on, the epidermal in growth splits, leaving a central shaft and a space called follicle in which the hair lies. The cells of the follicle bud off one or more masses of epidermal cells which later on develops into sebaceous glands. Within the follicle the hair shaft becomes surrounded by two layers of cells which do not go out beyond the limit of the follicle.

The inner layer is called Huxley's layer and the outer layer is called Henle's layer (Fig. 1). The hair shaft is entirely cellular and in cross-section shows three distinct regions—a central core or medulla, middle cortex and outer cuticle.

At the base of the follicle the hair forms a bulb like enlargement called root. Growth takes place at the root. Beyond this point the cells gradually die and the shaft or the projecting part thus becomes made up of dead and cornified cells.

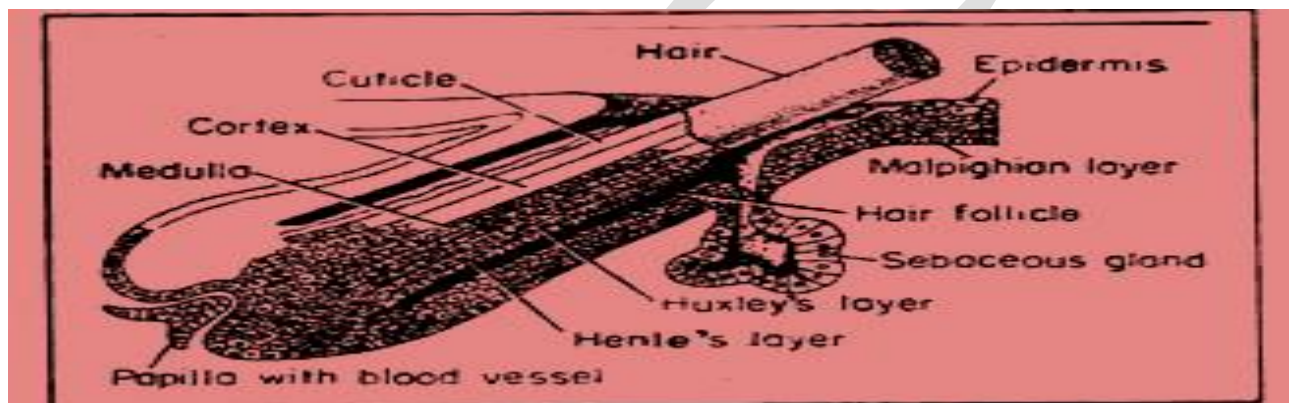


Fig:1 Sectional view of hair & location of Sebaceous gland.

Growth:

The growth of hair may be definitive or angora. Angora hairs grow to a considerable length and then are shed. The head hairs of man are of angora type. Definitive hairs, on the other hand, grow to a certain length and then stop growing. They are then shed but replaced very quickly. Eyebrows, eyelashes and body hairs are definitive type. Angora hairs may persist for several years but definitive hairs last for only a few months.

Hairs in different parts of the body show some variation in the direction in which they grow or slant. Hairs grow in different patterns, Called hair

currents. When hair currents diverge, parts occur and when they converge, crests or tufts occur.

Spiral arrangement of hairs results in whorls or vortices. The cowlick on the forehead of human being is an example of whorl. In most mammals the hair parts on the mid-dorsal line and slopes towards the ventral side, but the condition is reverse in sloths for their habit of hanging upside down.

### 3. Colour:

The colour of the hair is due to the presence of pigments in the intercellular spaces of the cortex. The nature and amount of pigments present determine the shade. Predominant pigment is normally brown.

But black and red pigments may also be present. Absence of both or one or different combination or dilutions of the two bring about the variations of shade. Lack of pigments and presence of air-spaces between the cells of the medulla imparts white colour to the hair.

Density:

Density of hair is variable in different mammals. Those living in cold climates of North and South hemispheres or at high altitudes possess thick hair coat. Tropical mammals have sparse hairs. The quality of a fur is determined by the degree of development of the under fur. The under fur consists of large number of short and densely arranged hairs interspersed between large and coarse hairs.

Modification:

The type of hair in different parts of the body of the same individual varies. **Mane of horses and lions are special type of hairs. Vibrissae on the snout of many mammals are special and sensitive hairs.** In spiny ant-

eater (*Tachyglossus*), hedgehog and porcupine the hairs in part have become modified into **spines or quills to act as organs of defence**. The coarse hair on the pig's back is modified to form stiff bristles.

#### 4. Claws, Nails and Hoofs:

The distal end of the digits in mammals is provided with either claws or nails or hoofs (Fig. 10.122). They are derived from the horny layer of the epidermis. The single fact that makes these structures different from all others epidermal structure is that they always grow parallel to the surface of the skin. Nails, hoofs and claws are built on the same architectural plan.

##### Claw:

A claw is composed of a scale-like plate which takes the dorsal position. The plate is called unguis. Another plate, called sub unguis, lies beneath or ventral to the unguis. The unguis is better developed. The claw covers the terminal bony phalanx to strengthen it. In mammalian claws, the sub-unguis is reduced in size and is almost continuous with the torus or pad at the end of the digit.

The claws in the members of the cat family (Fig. 2A) are retractile and the claws when not in use are withdrawn into a sheath. In lemurs the second digit on each hind limb is provided with claw while the other digits are provided with nails. In tarsier the second and third digits of the hind-foot are clawed, the others are with nails.

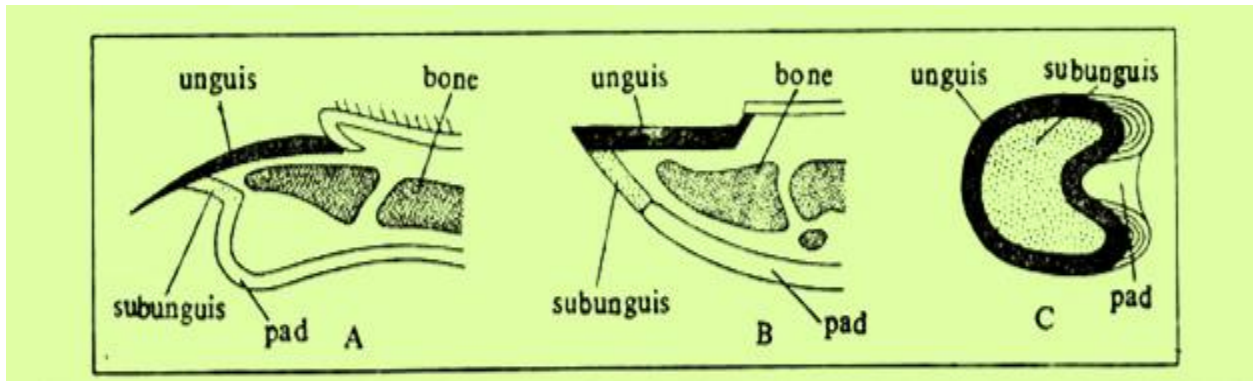


Fig.2: A: Claw B: Nail C: Hoof.

### Nail:

In nails the unguis is better developed. The unguis is broad and flat. The sub-unguis is much reduced and its remnant is present under the tip of the nail. The ‘root’ of the nail or the region from where the growth of the unguis takes place lies embedded in a pocket under the skin.

The pocket is called nail groove or sulcus unguis. Beneath the nail and its root lies the nail bed. The nail bed is made up of three distinct regions—proximal, middle and distal. The proximal part is known as matrix and it is concerned with the development of the nail. The matrix in man may be seen through the base of the thumb nail as a crescent-shaped area, called lunula.

### Hoof:

Hoofs are characteristics of ungulates. In hoofs the unguis is most well-developed and curves all the way round the ‘digital end enclosing the sub-unguis. The torus or pad lies just behind the hoof. The torus is known in case of hoofed mammals as frog. The unguis is of harder consistency than the sub-unguis (Fig. 2C).



## 5. Horns:

Excepting their presence in a few living lizards and in extinct dinosaurs, the horns are mammalian monopoly though they are found only in certain members of the order **Artiodactyla** and in Rhinoceros of the **Order Perissodactyla**. According to structure and mode of formation four types of horns are recognised (Fig. 3 and Fig.4).

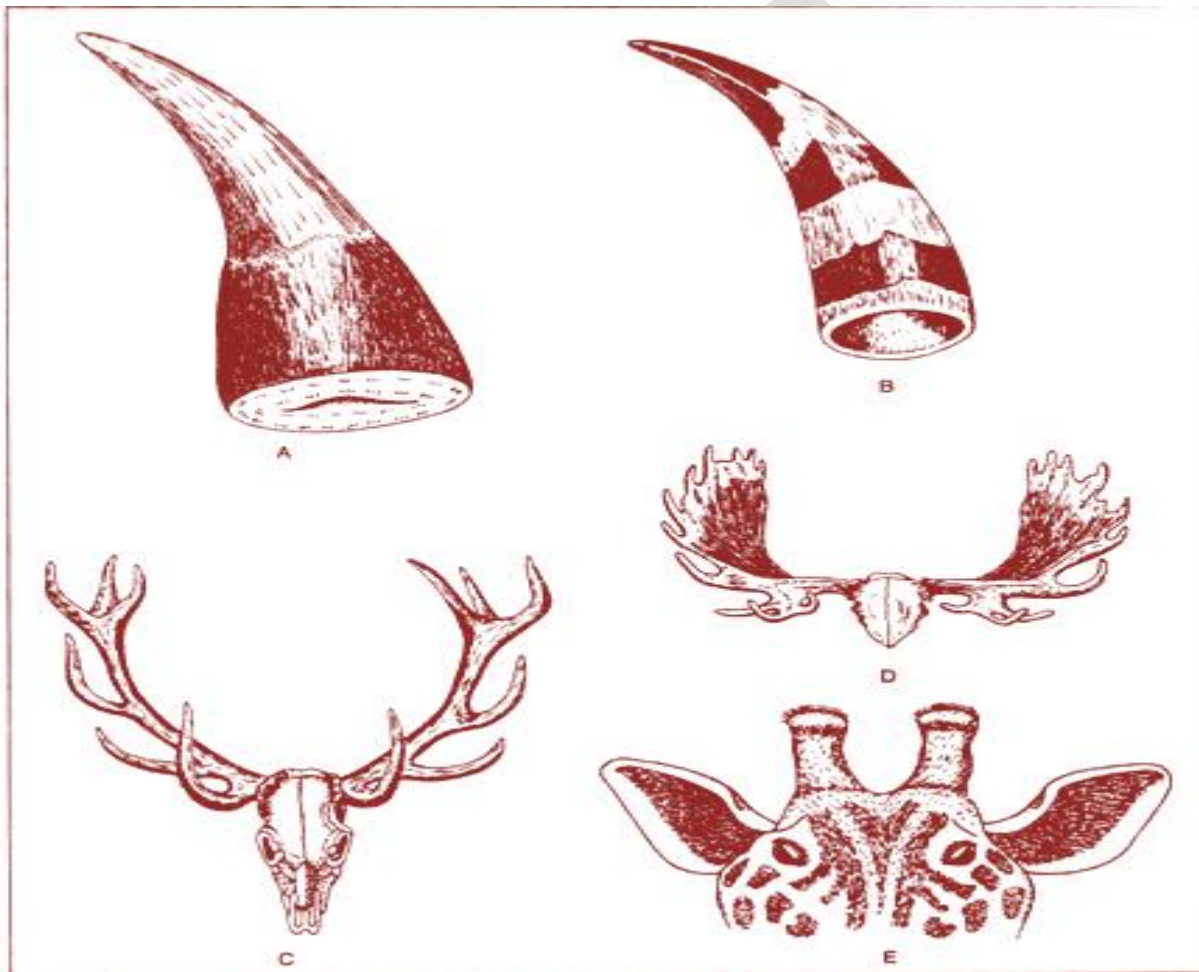


Fig.3 A: A Keratin fibre of Rhino. B: Hollow horn of Bovine C: Antler of a Red deer. D: antler of Moose. E: Giraffe Horn.

### Keratin-fibre horn:

Keratin-fibre horn is found only in the Rhinoceros (Fig. 3A). It is a hard conical structure located on the frontonasal region of the skull. It is composed of a cluster of long fibres cemented together by a mass of hard and keratinized cells growing from the epidermis.

Each fibre resembles a very thick hair and emerges from a dermal papilla. The fibres are not true hairs since their bases lack follicles. In Indian rhinoceros there is a single horn. In African rhinoceros there are two horns. The two horns are located on the same median line along the frontonasal bone and the larger one lies in front.

### Hollow horns:

Cattle, sheep, goats and buffaloes possess hollow horns (Fig. 3B). In certain species they are present only in males but in most both the males and females possess horns.

There is a pair of horns, one each on the frontal bone. The horn consists of a bony projection from the frontal bone of the skull. The projection is covered over by a cornified layer of epidermis. A cavity extends into the bony projection. The horny layer is never shed.

In very young animals the first indication of the future development of horn is seen in the formation of the os cornu. Os cornu is a loose button-like mass of bone cells which can be felt under the skin on the frontal bone. The os cornu later on becomes fused with the frontal bone. If the os cornu is destroyed by applying chemicals the horn fails to develop.

## Prong horns:

This is a unique type of horn found only in the antelope, *Antilocapra Americana* of the Western America. It consists of a conical projection on the frontal bone. A horny epidermal sheath covers the projection.

The sheath usually bears one side projection or Prong (Fig. 4D-F), but as many as three have been encountered. The epidermal sheath is shed with annual periodicity and a new epidermal sheath again covers the bony projection.

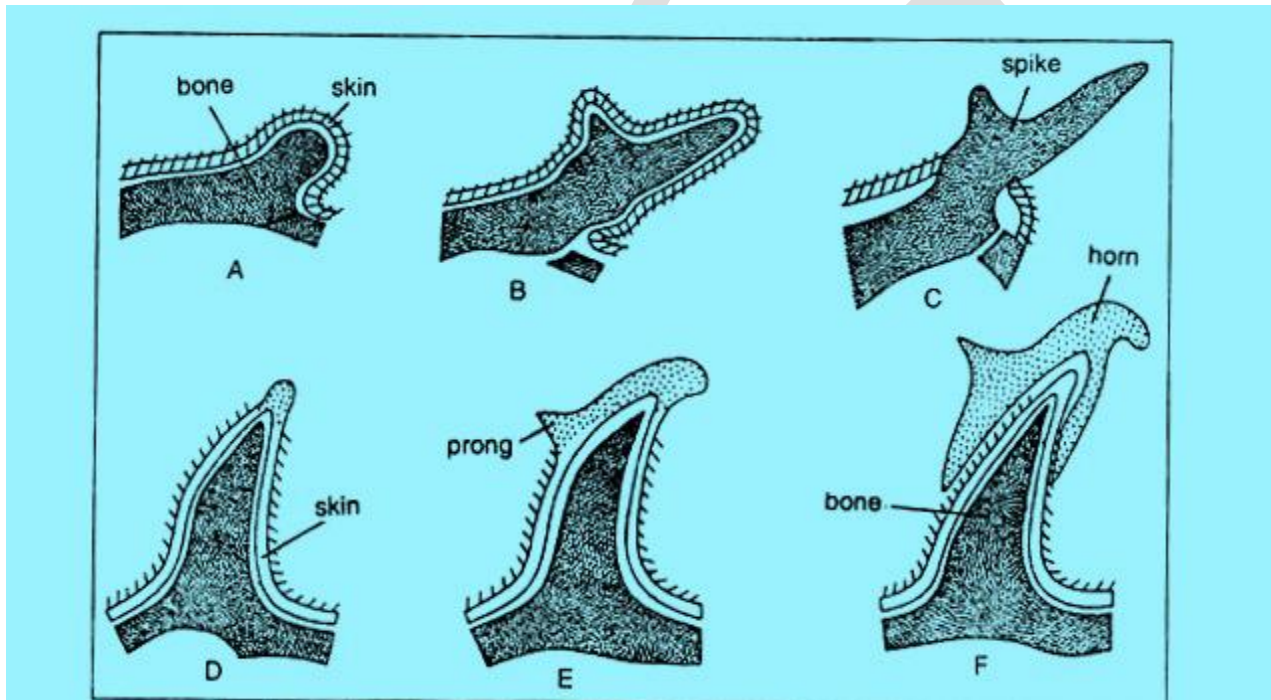


Fig: 4 A-C(Formation of Antler) & D-F(Formation of Prong Horn)

## 6. Antlers:

Antlers are present only in the male members of the deer family (Fig. 3C-D and 4A-C). In reindeer and caribou both the sexes bear antlers. When fully developed the antler is nothing but a solid bone and, as such, entirely mesodermal in origin.

Though it is better to consider the antlers as parts of the dermal skeleton it is discussed under the integumentary derivatives simply because the antler is formed under the influence of the integument.

During the early phase of growth of the antler an outgrowth on the frontal bone appears, one on each side. It remains covered with soft skin (Fig. 4A). The blood vessels on the overlying dermis bring minerals and other elements necessary for the growth of the structure. At this stage the antler is said to be 'in velvet'.

As autumn approaches, a wreath-like burr grows round the base of the antler. This burr cuts off blood supply to the skin and on the antler and as a result the skin dries, cracks and is ultimately rubbed off by the deer. At the end of the first season the antler appears as a single spike (Fig. 4C). A young buck with a single spike on each side is called a spike buck.

In the spring certain degenerative changes occur between the burr and the frontal bone and, as a result, the antler becomes loose and finally is shed. The skin closes the area. Soon a new antler begins to develop but this time it is branched.

The developing antler remains in velvet until autumn approaches. Then it comes up in the same fashion as described and is again shed in the following spring. Each time new branches appear making the structure very complicated.

The growth of antler is regulated by the secretions of both testes and anterior lobe of the pituitary. If castration is made before eight months of age antlers never grow. If castration is made at a stage when the antlers are in velvet, antlers do not develop and remain permanently in velvet.

Castration of deer with fully grown antler results in its prompt shedding. Subsequently new antler is formed but they remain permanently in velvet. Antler growth can be induced in female deer by the administration of the male hormone—Testosterone.

In giraffe both sexes possess small and inconspicuous antlers (Fig. 3E). These are developed by short bony protections of the frontal bones and remain permanently in velvet.

## 7. Epidermal Scales:

Many mammals possess epidermal scales. Excepting the scaly ant-eaters and armadillos the scales, when present, remain confined in tail and paws. Since the scales and hairs in mammals are found in close association with each other it is believed that hairs have been derived from scales.

Epidermal:

In ant-eaters (Manis) the body, excepting on the ventral surface, is covered with large, overlapping and horny scales. The scales are typically reptilian in nature. But ecdysis occurs singly. In armadillos the scales are large and with hairs are interspersed over the entire body (Fig.

10.125), and also the scales fuse to form plates over the head, shoulders

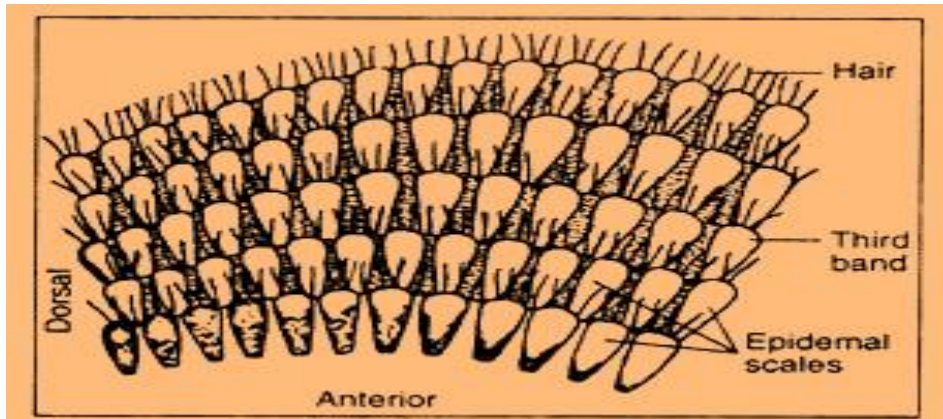


Fig. 5: Scales of hair on the body of Armadillos.

And hind parts.

Ecdysis, in true sense, is absent but a process of wearing away of the scales from the surface and replacement from beneath is present. Fossil giant armadillos (*Qlyptodon*) a related type of modern armadillos had thick fused scales.

Epidermal scales are present on the tails of rats, mouse, mole, shrew, beaver and musk-rat. These scales are arranged in an imbricated fashion though the degree of cornification is not very pronounced and there is no ecdysis. Embryonic scales found in foetus of European hedgehog and brown bear.

In most mammals the under-surface of the hands and feet bear evidences of former presence of scales. The friction ridges according to some represent such rudimentary scales. On the under surface of the foot of rat there are distinct and elevated pads called *Tori*. Friction ridges are located on these *tori*. There are eleven such *tori* in the foot of rat.

Of these five are digital *tori* located at the tip of the digits, four are inter-digital being placed between the spaces intermediate between the digits,

one is thenar at the base of the first digit and one is hypothenar at the base of the fifth digit.

THEG